

Table 2. Different anatomical, histopathological & surgical data of cheek region (group II).

Affected site (patients' number and percentage)	Surgical procedures	Number and percentage	Clinico-pathological data
• Left side (n=8), (10.6%)	<ul style="list-style-type: none"> • Excision & primary closure • Rotational flap • Rhomboid flap • Left maxillectomy & delatopectoral flap • Serial excision 	<ul style="list-style-type: none"> • 3 (4%) • 2 (2.6%) • 1(1.3%) • 1(1.3%) • 1(1.3%) 	<ul style="list-style-type: none"> • SCC in one patient, hamartoma in one, multiple intradermal naevus in one. • BCC in both patients. • BCC. • SCC of the left maxilla • Haemangioma
• Right side (n=6), (8%)	<ul style="list-style-type: none"> • Excision & primary closure • Rotational flap • Cheek advancement flap 	<ul style="list-style-type: none"> • 2 (2.6%) • 3 (4%) • 1 (1.3%) 	<ul style="list-style-type: none"> • SCC in one patient and BCC in the other. • BCC in 2 and intradermal naevus in one. • BCC.

Table 3. Different anatomical, histopathological & surgical data of group III.

Affected site patients' number and percentage	Surgical procedures	Number and percentage	Clinico-pathological data
• Midline (n=8), (10.6%)	• Excision & primary closure	• 8(10.6%)	• Dermoid cysts in 4, BCC in 2 trichilemmal cyst in one and pyogenic granuloma in one.
• Left side (n=3), (4%)	<ul style="list-style-type: none"> • Rhomboid flap • Full thickness graft • Double pedicle advancement flap 	<ul style="list-style-type: none"> • 1(1.3%) • 1(1.3%) • 1(1.3%) 	<ul style="list-style-type: none"> • SCC • SCC • Compound naevus of the left brow
• Combined right and left side (n=1), (1.3%)	• Double M flap for forehead lesion and split-thickness graft and pre-auricular flap for the left temple and right auricle respectively	• 1(1.3%)	• Multiple BCC of the forehead, left temple and right auricle

Table 4. Different anatomical, histopathological & surgical data of group IV.

Affected site patients' number and percentage	Surgical procedures	Number and percentage	Clinico-pathological data
• Ala of the nose (n=5), (6.6%)	<ul style="list-style-type: none"> • Bilobed flap • Forhead flap 	<ul style="list-style-type: none"> • 4 (5.3%) • 1 (1.3%) 	<ul style="list-style-type: none"> • BCC • BCC
• Tip of the nose (n=4), (5.3%)	<ul style="list-style-type: none"> • Melolabial flap • Rhomboid flap • Full-thickness graft 	<ul style="list-style-type: none"> • 2 ((2.6%) • 1(1.3%) • 1 (1.3%) 	<ul style="list-style-type: none"> • BCC • BCC • BCC
• Dorsum (n=3), (4%)	<ul style="list-style-type: none"> • Glabellar flap • Excision & primary closure • Transposition flap 	<ul style="list-style-type: none"> • 1 (1.3%) • 1 (1.3%) • 1 (1.3%) 	<ul style="list-style-type: none"> • BCC • BCC • Sweat gland carcinoma confirmed histopathologically to be adenoid-cystic type.

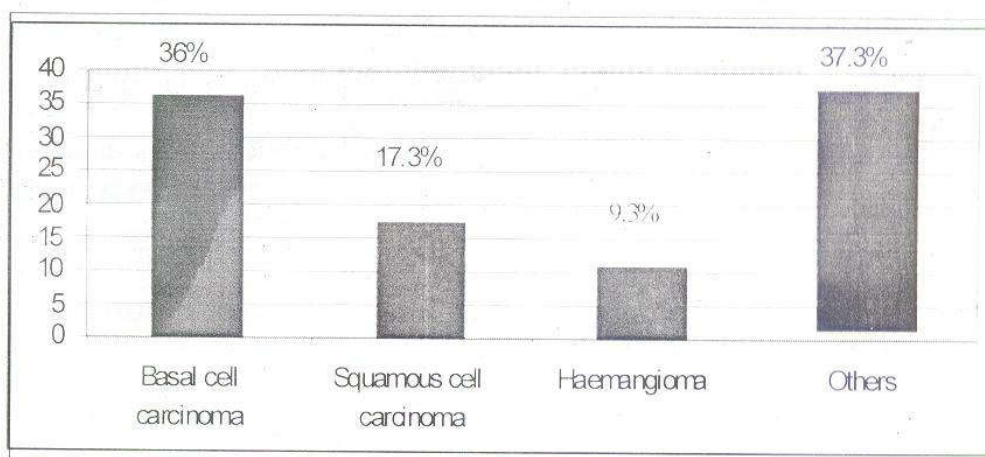
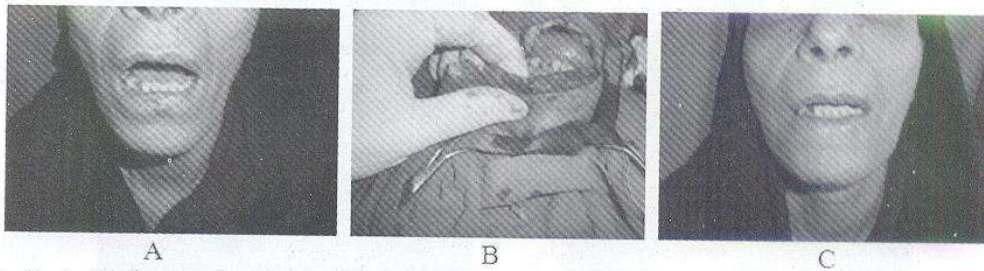


Figure (2) Incidence of each tumour type in this study.

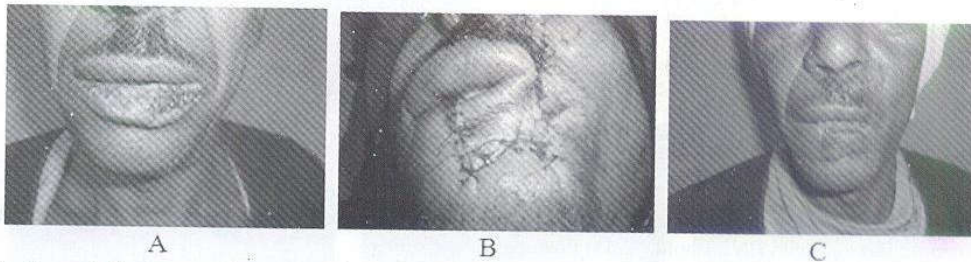
Table 6. Aesthetic and functional outcome of patients.

Region	Functional & aesthetic outcome	No. & % of patients
1-Oral and perioral region (34 patients)	Excellent	25 (33.33%)
	Very good	3 (4%)
	Good	6 (8%)
2-Cheek region (14 Patients)	Excellent	6 (8%)
	Very good	2 (2.6%)
	Good	4 (5.3%)
	Fair	2 (2.6%)
3-Forhead region (12 Patients)	Excellent	9 (12%)
	Very good	1 (1.3%)
	Good	2 (2.6%)
4- Nasal region (12 Patient)	Excellent	6 (8%)
	Very good	5 (6.6%)
	Good	1 (1.3%)
5-periorbital region (3 Patients)	Excellent	2 (2.6%)
	Very good	1 (1.3%)
Total No. of patients		75 100%

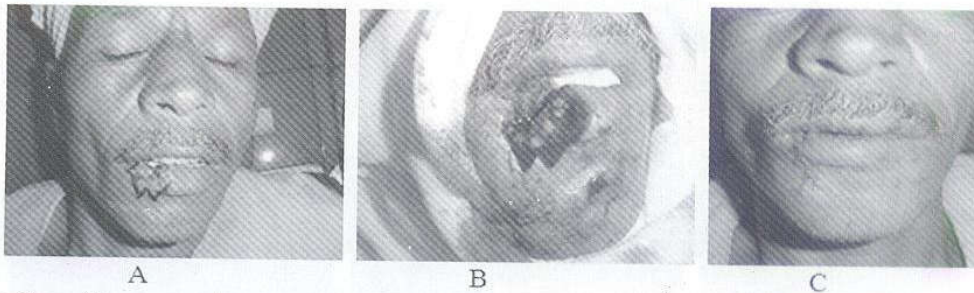
A: Group 1: Patients with oral and perioral tumours:



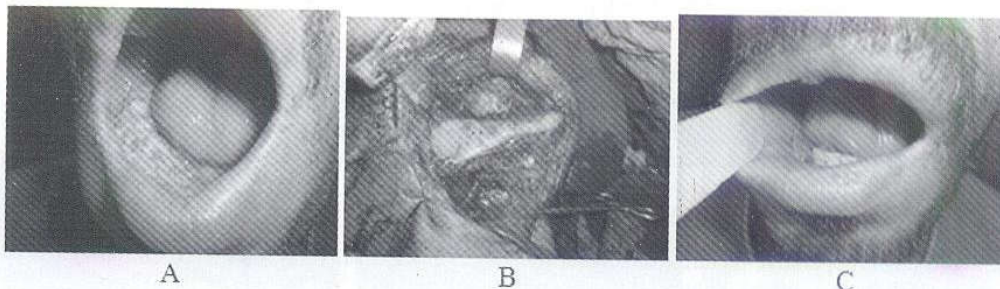
1. Photo (A) Preoperative picture (Squamous cell carcinoma of the lower lip-carcinoma in situ), (B) intraoperative picture (Vermilinectomy and mucosal advancement), (C) Postoperative picture.



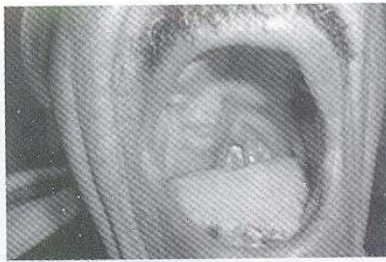
2. Photo (A) Preoperative picture (Squamous cell carcinoma of the lower lip), (B) Intraoperative picture (Abbé flap), (C) Postoperative picture.



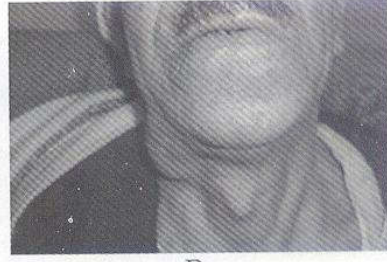
3. Photo (A) preoperative picture (Squamous cell carcinoma of the lower lip), (B) Intraoperative picture (W excision and primary closure), (C) postoperative picture.



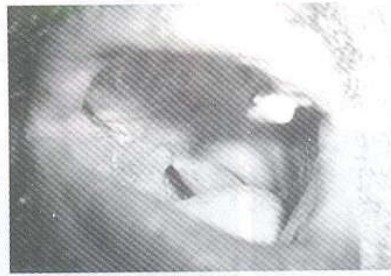4. Photo (A) Preoperative picture (Squamous cell carcinoma of the right gingiva), (B) Intraoperative picture (excision of the mass & hemimandibulectomy), (C) Postoperative picture.



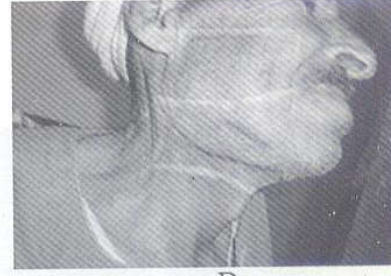A



B



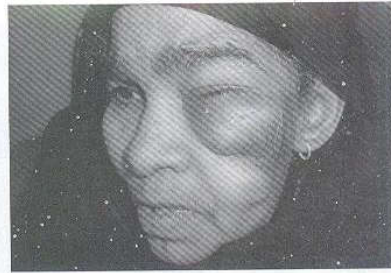C



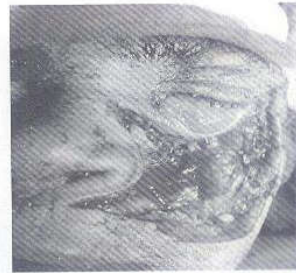D

5. Photo (A,B) Preoperative picture (Minor salivary gland adenocarcinoma of the palate with right submandibular enlarged LN). Photo (C, D) Postoperative picture.

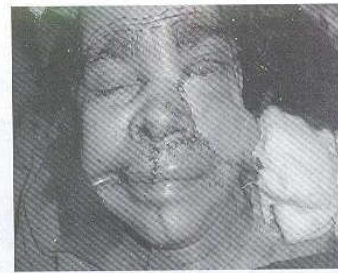B-Group II: patients with tumour in cheek region:



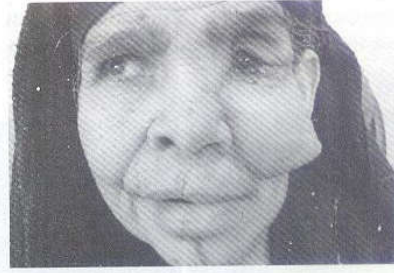A



B



C



D

6. Photo (A) Preoperative picture (Squamous cell carcinoma left Maxilla). Photo (B, C) Intraoperative picture (Deltpectoral flap), Photo (D) Postoperative.